

Appetizer

Neck ache and radiating neck pain to the shoulder and arm are frequent symptoms in general practice. This article provides a systematic review of the main causes and pitfalls.

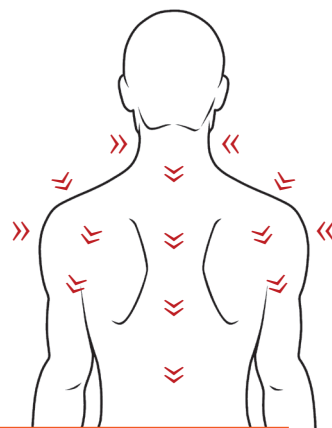


Danish Society of Musculoskeletal Medicine

Causes of Neck Ache

- and radiating pain to the shoulder and arm

● By Peter Silbye, MD and GP



Kontakt

peter_silbye@dadlnet.dk

Biografi

Peter Silbye, MD with specialty training in General Practice, postgraduate diploma in Musculoskeletal Medicine and Practice Consultant at the Department of Rheumatology, Køge Hospital, Denmark.

RESUME: Radiating pain from the neck to the shoulder and the arm is not always a sign of cervical disc herniation, which is relatively rare. A thorough examination can sometimes reveal neck problems, even in patients in whom neck issues were not the first thing that came to mind.

MÅNEDSSKRIFT
for almen praksis

Musculoskeletal problems take a strong presence in daily general practice; it is one of the most common reasons for encounter. The general practitioner (GP) must assess whether a presented problem belongs to the 90% self-limiting non-specific musculoskeletal problems that usually resolve on their own. Thorough examination and explanation will usually suffice for these, but this must sometimes be supplemented with manual therapy provided by own GP, physiotherapist or chiropractor. "Red flags", such as serious root pressure with paresis, malign disorders, severe rheumatologic diseases, fractures and common symptoms of a herniated disc, constitute the last 10%. (1)

The Danish Society for Musculoskeletal Medicine offers training of doctors in both clinical diagnosis and manual treatment of patients with musculoskeletal conditions. See Figure 1.

In this article, I will present the main causes of radiating pain from the neck to the shoulder and arm while bearing in mind that radiating pain to the arm is not necessarily a sign of a herniated disk. This topic was inspired by my work as a general practice consultant at the Department of Rheumatology at Køge Hospital in Denmark. I came across a referral which had been rejected by the department; the referral was



Diskusprolaps i nakken – rodtryk
- <http://www.medibox.dk/show.php?docid=152>

Case 1: Jens, aged 48

Referred for cervical radiculopathy owing to radiating pain from the right arm to hand.
Referral rejected by the Department of Rheumatology.
Suffering from pain and needs a lot of pain-killing drugs.
On sick leave from work.

Figure 1 /
Danish Society for Musculoskeletal Medicine (DSMM)

- Is a Danish society for medical specialists with approx. 540 members, primarily GPs and rheumatologists
- Organizes courses in diagnostics and treatment of musculoskeletal disorders
- Organizes an annual meeting for all interested Danish GPs
- Offers a medical diploma degree consisting of 300 teaching sessions.
- Home page: www.dsmm.org (in Danish)

considered “incomplete” as no objective findings had been stated to support the diagnosis. See Case 1.

Causes of neck pain are divided into three main groups: upper, middle and lower cervical syndromes.

Upper cervical syndromes

The upper segments, C1 and C2 can be influenced by direct trauma (e.g. whiplash) or locking, usually because of muscle tightness. In addition to local pain and head ache, the patient often has very diffuse symptoms – so-called vegetative symptoms, which may appear as uncharacteristic



Whiplash – Piskesmæld
- <http://www.medibox.dk/show.php?docid=12865>

Figure 2 /
Upper cervical syndromes.

- Head ache
- Dizziness
- Visual disturbances
- Hearing disturbances
- Facial symptoms
- Difficulty speaking and swallowing
- Drop attacks



The radiating pains may appear because plexus brachialis is affected at some place

dizziness, visual and hearing disturbances, facial pain, swallowing difficulties and memory or concentration problems. See Figure 2.

These symptoms are often seen in patients with whiplash, as also mentioned above, but are also commonly reported by patients who may not initially make you suspect neck-related problems. See Case 2. If the neck is investigated, you will often find that a "fixation" in the upper cervical spine – a crick in the neck – is causing the problems.

Case 2: Ulla, aged 28

- Has a cold with a sense of oppression over the right eye and down into the jaw.
- Has a lump-in-the-throat feeling.
- Knows the symptoms from previous episodes of sinusitis.
- Requests penicillin.
- Afebrile, normal C-reactive protein (CRP) level.

Middle cervical syndromes

The patient will usually complain about "pains in the neck". These pains can be caused by segmental dysfunction, which was formerly referred to as facet joint syndrome or "crick in the neck" – and may appear as degenerative or muscular pathologies. Segmental dysfunction is defined as changed mobility between two vertebral segments, but it does not say anything about the cause of it.

Lower cervical syndromes

The patient will usually complain about neck pain radiating to the shoulder and down into the arm. If the patient points to a specific location in the shoulder that hurts, it is generally a good idea to first consider local shoulder problems. If the patient keeps working the hand round on the shoulder when asked to point to the location that hurts, this may suggest problems with the spinal column or segmental dysfunction.

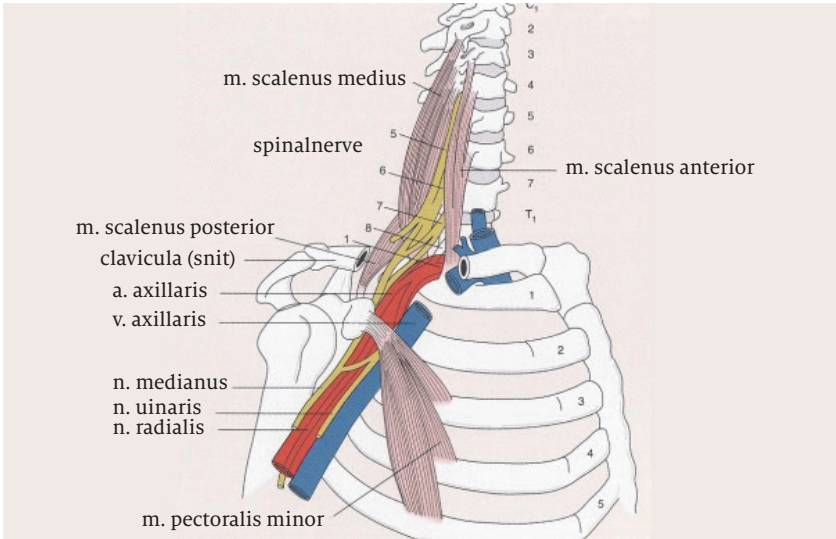
The radiating pains may appear because plexus brachialis is affected at some place.

Where can the plexus brachialis nerves get pinched?

Let us start at the top (2). See Figure 3.

1. Root pressure may obviously affect the nerve roots and cause radicular symptoms, i.e. radiating pains along the dermatomes, changes in

Figure 3 /
Illustration: Birgitte
Lerche. Rheumatology.
FADL Publishing
Company.



reflexes and muscular endurance in the affected cervical innervated muscles or changes in sensibility. See Table 1. The Foraminal Compression Test aiming at aggravating the radicular symptoms is still the most important and specific test, although it is not very sensitive. The test is performed by side-bending, rotating and extending co-lumna cervicalis and sometimes also placing a slight downward pressure on the head.

2. Degenerative changes with arthrosis in facet joints and uncovertebral joints may present with similar symptoms.

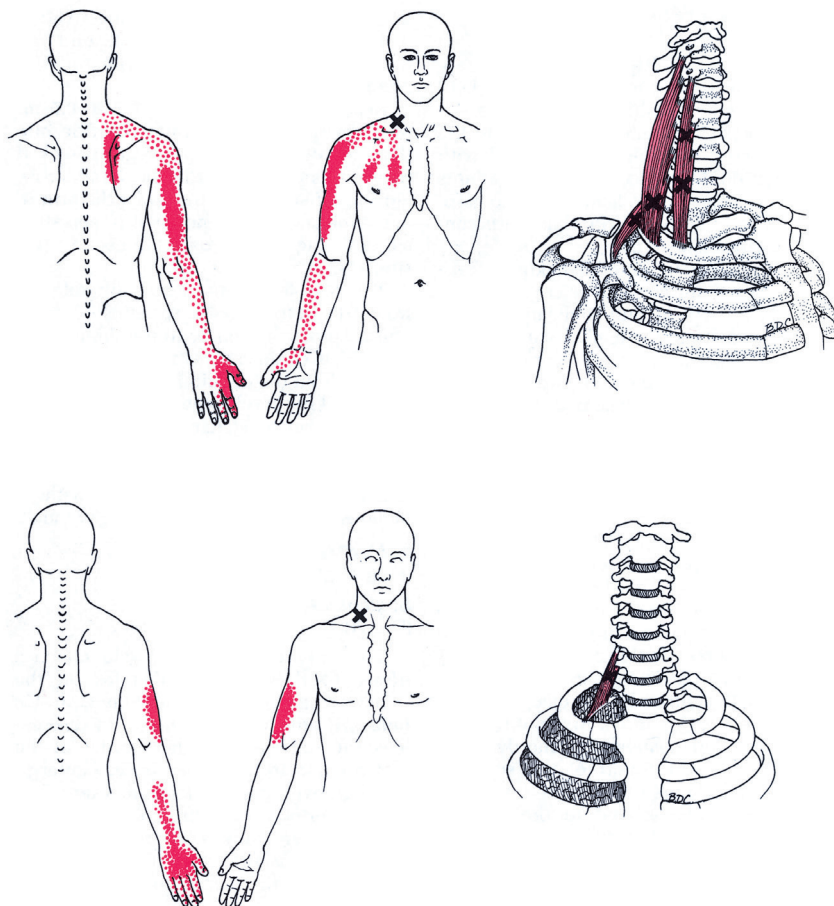
Table 1 /
Testing of motor roots

Nerve root	Muscle	Endurance	Sensibility	Reflex
C1 and C2	Deep anterior neck muscles	Ventraflexion of col. cervicalis	Regio occipitalis	-
C3 and C4	M. levator scapulae	Shoulder lift	Reg. subman-dibularis (C3) Reg. colli lat. et subclav. (C4)	-
C5 and C6	M. biceps brachii (C5) M. infraspinatus M. teres minor (C6)	Elbow reflexion Shoulder joint external rotation	Radialside upper arm (C5) Radialside forearm, 1st and 2nd finger (C6)	Biceps (C5-C6)
C7 and C8	M. triceps brachii (C7) M. adb. poll. (C7) M. abd. dig. v. (C8)	Elbow extension Abd. 1st finger Abd. 5th finger	3rd finger (C7) Ulnarside forearm and 4th and 5th finger (C8)	Triceps (C6-C7) Brachioradialis (C5-C8)

Figure 4 /

Radiating pain from
trigger points in the
scalene muscles

*Illustration: Lippincott
Williams & Wilkins,
1999. Travel & Simon:
Myofascial pain and
dysfunction.*



3. Segmental dysfunction, a crick in the neck causing changes in the mobility of the segment, will often cause both neck ache and diffuse pains in the arm – also because the cervical segmental dysfunction will always influence the scalene muscles that attach to the processus transversus on the cervical vertebra. A tightening of the scalene muscles might then “squeeze” the plexus brachialis. The trigger points in the scalene muscles will also typically cause radiating pains in arm and hand (3). See Figure 4.
4. Huge impact of m. scalenius medius and posterior is seen, for example, in the case of whiplash injury. The head will first be fully extended followed by a forward flexion and rotation of the torso around the seat belt. This will cause a sudden pull in the scalene muscles, which may pull up costa 1 and result in a subluxation.

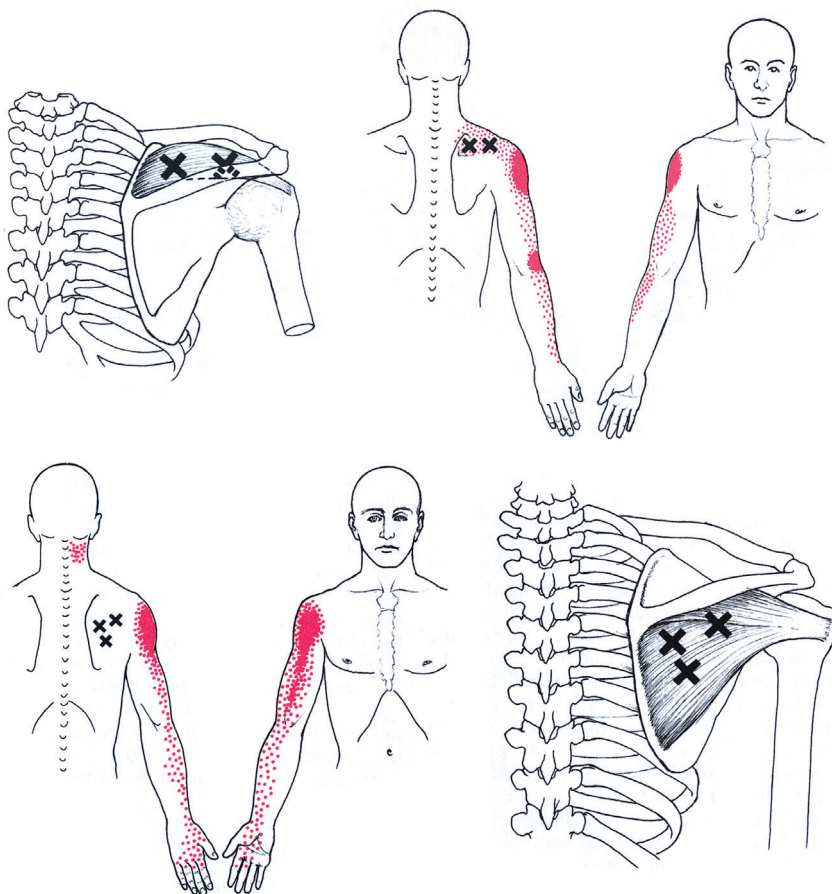


Anatomi læger,
skulder og overarm
- [http://www.medibox.dk/
show.php?docid=5669](http://www.medibox.dk/show.php?docid=5669)

Figure 5 /

Radiating pain from trigger points in m. supraspinatus and m. infraspinatus

Illustration: Lippincott Williams & Wilkins, 1999. Travel & Simon: Myofascial pain and dysfunction.



Plexus brachialis, vessels and nerves will then be affected by their “ride” across the first rib. This is the reason why many patients with whiplash from countries with right-hand traffic complain about diffuse pains and sensory disturbances in the right arm if they happened to be the driver. The driver’s seat belt is fastened in the left side, and the right side of the body will, therefore, be exposed to the strongest actions. The body will be thrown into flexion and rotation to the left with the seat belt as the rotation axis; unlike if you are a passenger.

5. Another very common cause is tightening of m. pectoralis minor. Most of us tend to spend a long time in front of the computer with hunched shoulders that often lead to tight and sore trigger points in m. pectoralis minor. The muscle is attached to processus coracoi-

deus, runs across plexus and fastens at costa 3-5. Consequently, contraction (shortening) of the muscle may place pressure on the vessels and nerves, which may result in diffuse pains radiating down into the arm. You may even feel the very tense trigger point in the muscle. See Figure 3.

6. Other muscles than the scalene muscles also have trigger points that may lead to diffuse radiating pains into the arm and hand. The most common is m. infraspinatus, which may cause pains into the hand, and the supraspinatus, which mostly causes pains in the elbow (2). See Figure 5. If you have a smart phone, you may buy a rather splendid app called Muscle Trigger Points for a small amount of money. This app is a good investment if you wish to brush up your knowledge of anatomy and may also be used as an illustration for the patients.

Key messages

Radiating pain to shoulder and arm is not always caused by cervical disc herniation. In fact, this is rarely the reason for nerve compression, which is mostly caused by other factors.

- Radiating pains that do not origin from the musculoskeletal system should always be investigated.
- Systematic anatomical investigation is a critical element of accurate diagnosis.
- Clinical education courses focussing on specific musculoskeletal topics might be helpful.

Financial conflicts of interest: none reported ●

References

1. Danish College of General Practitioners, Diagnostik og behandling af lændesmerter i almen praksis, klinisk vejledning [Diagnosis and treatment of lower back pain in general practice, Danish clinical guidelines], 2006.
2. Pødenphant J, Jacobsen S, Manniche C, Stengaard-Pedersen K and Tarp U (ed.), Reumatologi [Rheumatology], FADL Publishing Company, third edition, 2012.
3. Simons DG, Travell JG and Simons LS, Myofascial pain and dysfunction. The trigger point manual, vol. 1, 1998.

