



Syndromer omkring bækkenet

differentialdiagnoser, "Red flags"

Palle Holck
Speciallæge i reumatologi og intern medicin
Idræts- og dykkerlæge
Overlæge
Regionshospitalet Silkeborg
palle.holck@dadlnet.dk



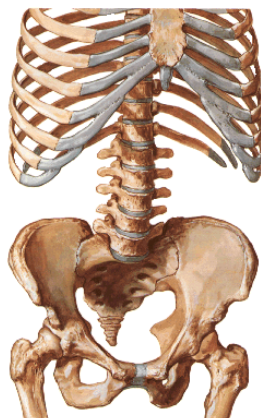
Anatomi & biomekanik



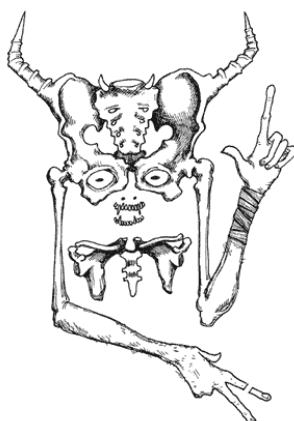– Var det ikke nemmere om De nævnede en masse symptomer, så kan jeg bare sige, hvilke jeg kender ...



Anatomi & biomekanik



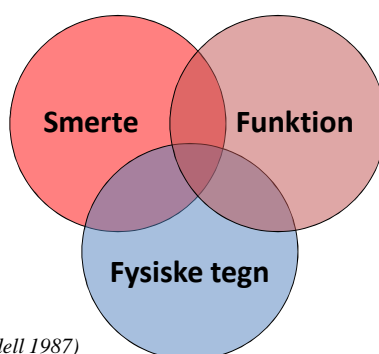
Anatomi & biomekanik



Pigerne mod drengene...



Anatomi & biomekanik



(Waddell 1987)

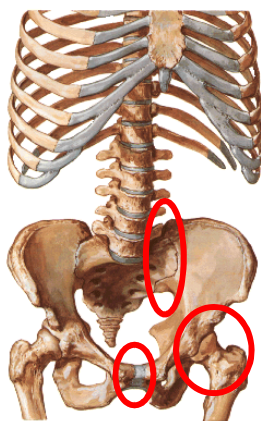


Anatomi & biomekanik

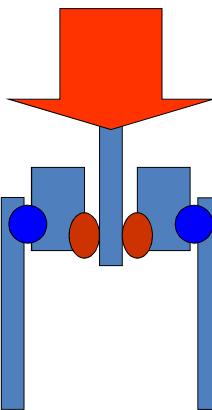
- Artikuloosøst
- Tendinøs
- Myofacielt
- Neuropatisk
- Refererede fænomener
 - Indre organer
 - Andre regioner



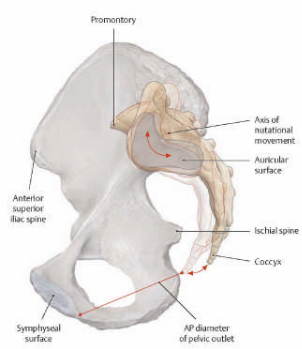
Anatomi & biomekanik



Anatomi & biomekanik



Anatomi & biomekanik



B Nutation in the sacroiliac joint
Right half of pelvis, medial view.

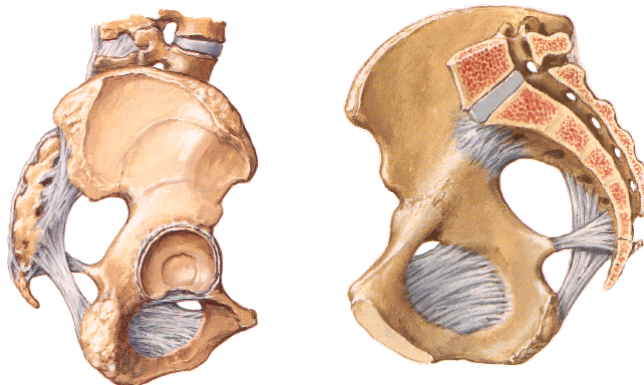
Illustrator: Karl Wesker

pp. 116-117

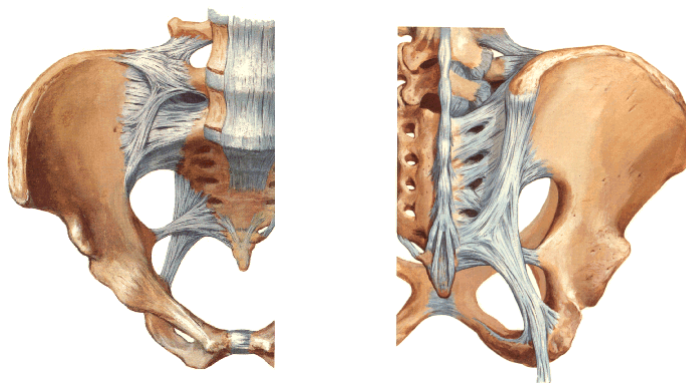
Schaenke et al. THIEME Atlas of Anatomy • General Anatomy and Musculoskeletal System
© THIEME 2007 • All rights reserved. Usage subject to terms of use. • www.thieme.com/ta



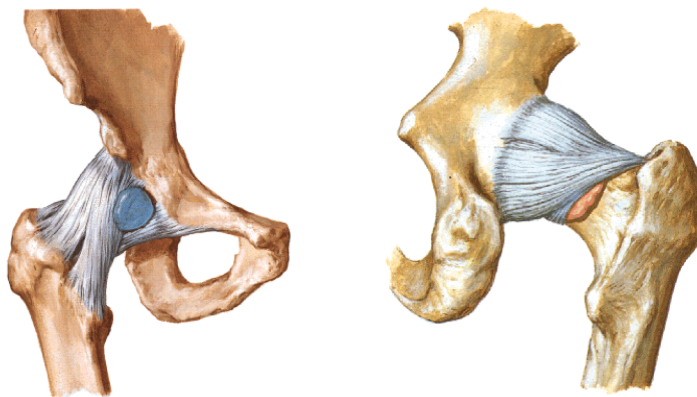
Anatomi & biomekanik



Plan

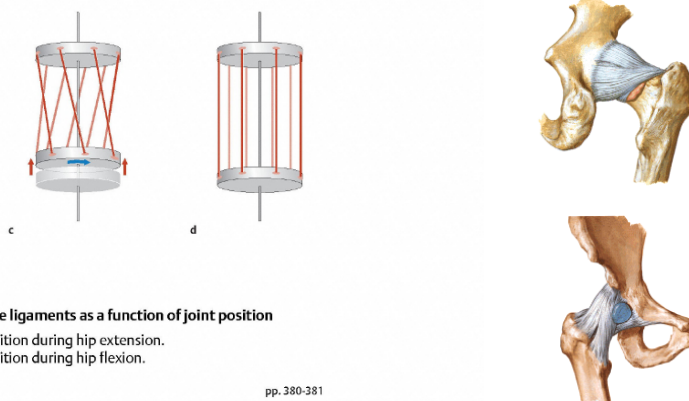


Anatomi & biomekanik



13

Anatomi & biomekanik



C Actions of the ligaments as a function of joint position

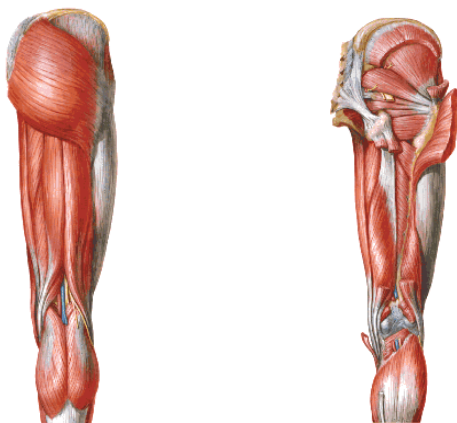
- c Ligament position during hip extension.
- d Ligament position during hip flexion.

Illustrator: Karl Wesker pp. 380-381
 Schuenke et al. THIEME Atlas of Anatomy • General Anatomy and Musculoskeletal System
 © THIEME 2007 • All rights reserved. Usage subject to terms of use. • www.thieme.com/ta



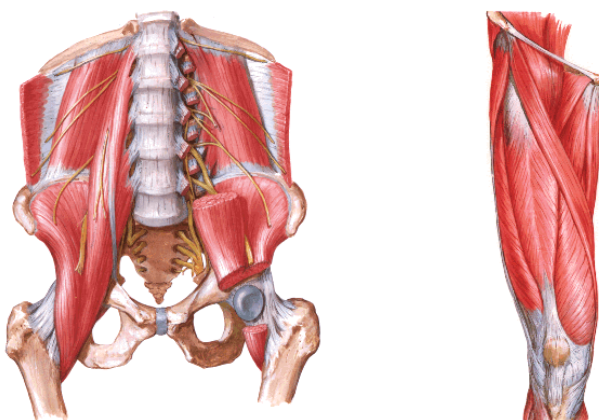
14

Anatomi & biomekanik



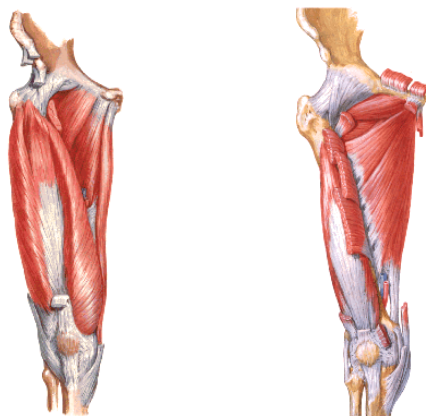
15

Anatomi & biomekanik



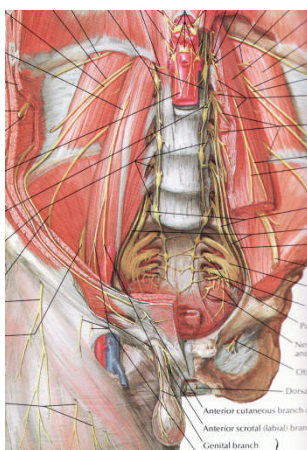
16

Anatomi & biomekanik



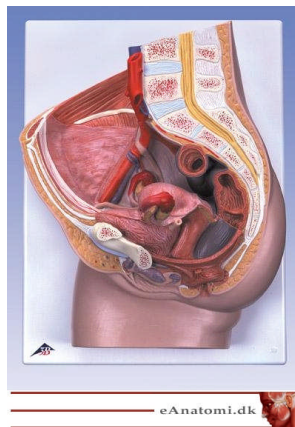
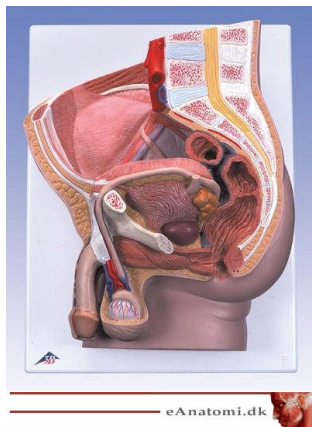
17

Anatomi & biomekanik

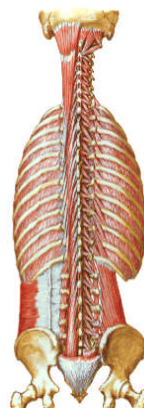
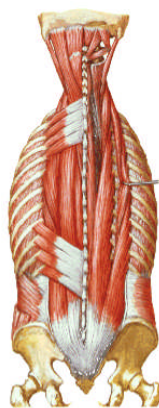
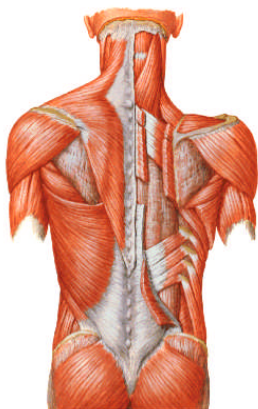


18

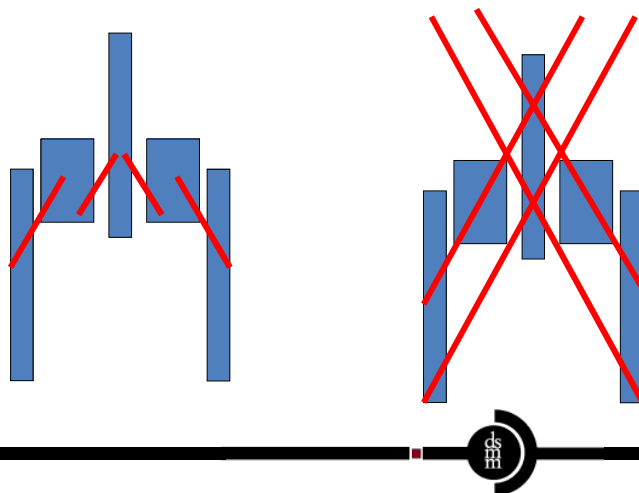
Anatomi & biomekanik



Anatomi & biomekanik



Anatomi & biomekanik



Anatomi & biomekanik

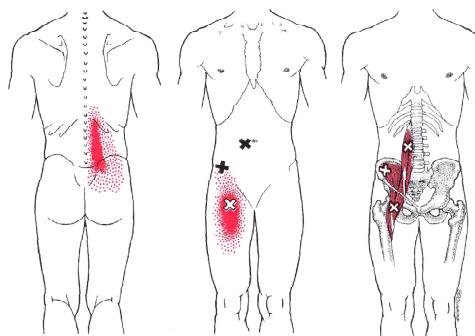


Figure 5.1. Pattern of pain (bright red) referred from palpable myofascial trigger points (X) in the right iliopsoas muscle (darker red). The essential pain referral zone is solid red; the spill-over pattern is stippled.

Anatomi & biomekanik

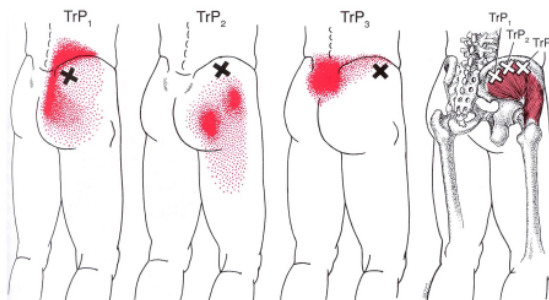


Figure 8.1. Pain patterns (bright red) referred from trigger points (TrPs) (Xs) in the right gluteus medius muscle (darker red). The essential pain pattern is solid red, and the spillover pattern is stippled. The most medial TrP, refers pain primarily to the crest of the ilium, to the region of the sacroiliac joint, and to the

sacrum. The TrP₂ area is located more cephalad and laterally, and refers pain caudally to the buttock and to the upper thigh posteriorly and laterally. The most anterior TrP₃ occurs less often and refers pain bilaterally over the sacrum and into the lowest lumbar region.



Anatomi & biomekanik

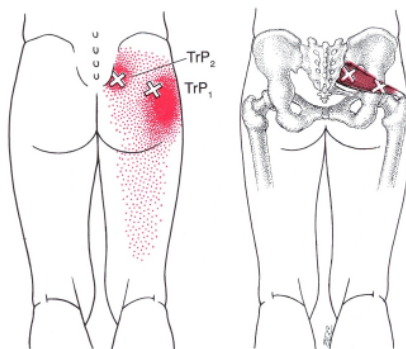


Figure 10.1. Composite pattern of pain (bright red) referred from trigger points (TrPs) (Xs) in the right piriformis muscle (darker red). The lateral X (TrP₁) indicates the most common TrP location. The red stip-

pling locates the spillover part of the pattern that may be felt as less intense pain than that of the essential pattern (solid red). Spillover pain may be absent.



Anatomi & biomekanik



■ Det farlige

- Infektion
- Neoplasi
- Systemsygdom


■ Det akutte

- Fraktur
- Luksation
- Kar-/nervelæsion

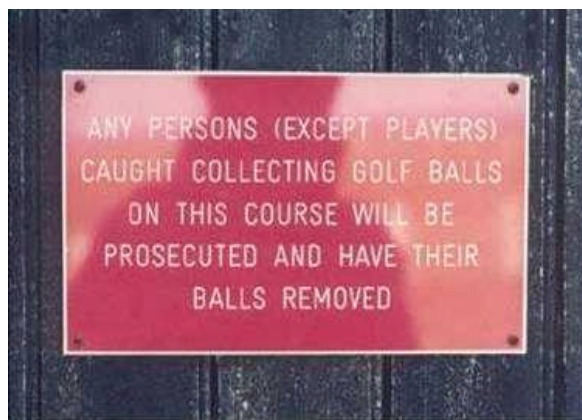■



Anatomi & biomekanik



Anatomi & biomekanik




Anatomi & biomekanik

<i>Individuelle faktorer</i>	<ul style="list-style-type: none"> - Køn og alder - Overvægt - Arvelighed - Rygning - Komorbiditet
<i>Psykosociale faktorer</i>	<ul style="list-style-type: none"> - Høje krav - Lav jobkontrol - Lav indflydelse - Manglende social støtte - Lav jobtilfredshed - Ængstelse - Bekymring - Depressivitet - Stress
<i>Arbejdsrelaterede faktorer</i>	<ul style="list-style-type: none"> - Arbejdsstilling - Gentagne bevægelser - Tungt arbejde - Kombination af tungt arbejde og gentagne bevægelser - Kombination af gentagne bevægelser og kulde



Anatomi & biomekanik

Inflammation vs. degeneration

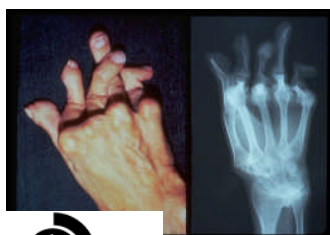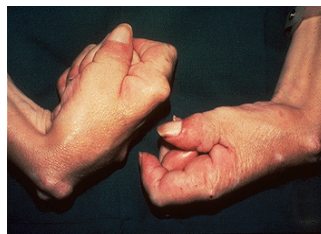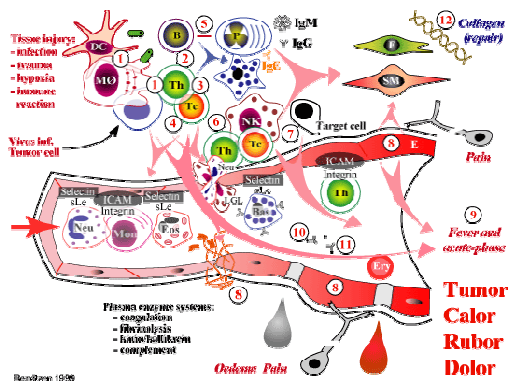


Anatomi & biomekanik

- Varme
- Rødme
- Smerte
- Hævelse
- Funktionstab



Anatomi & biomekanik

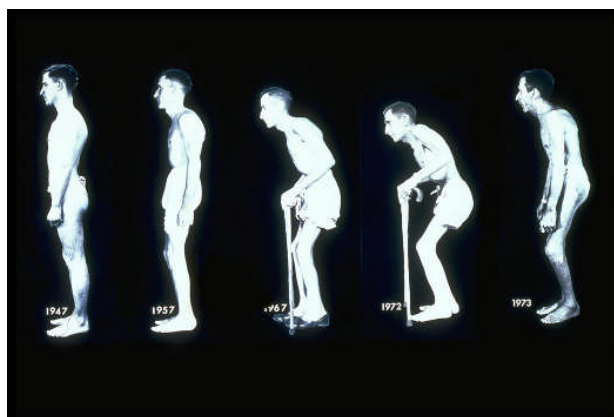

Anatomi & biomekanik

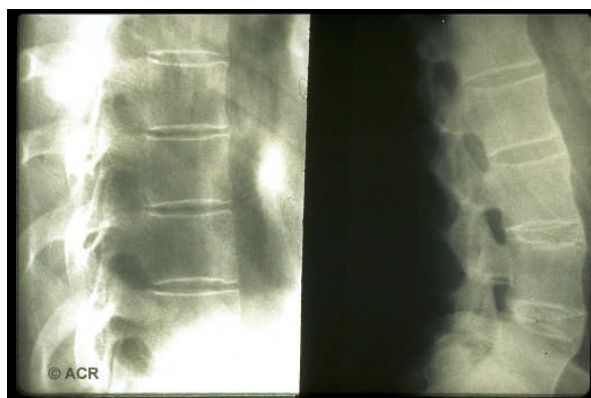
Smerten



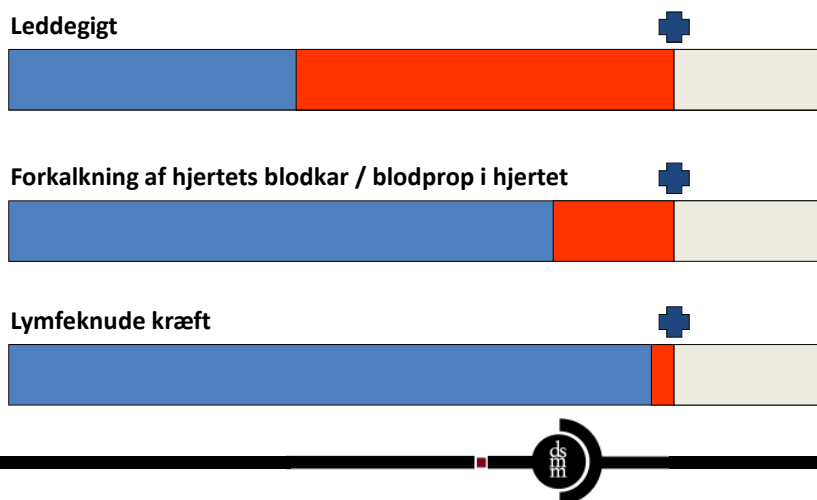
Anatomi & biomekanik



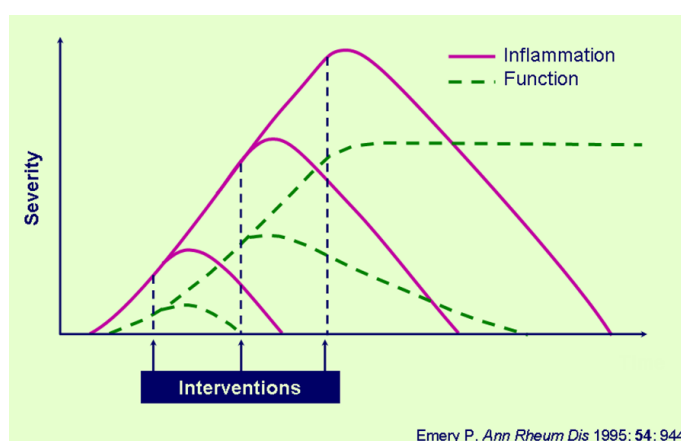
Anatomi & biomekanik



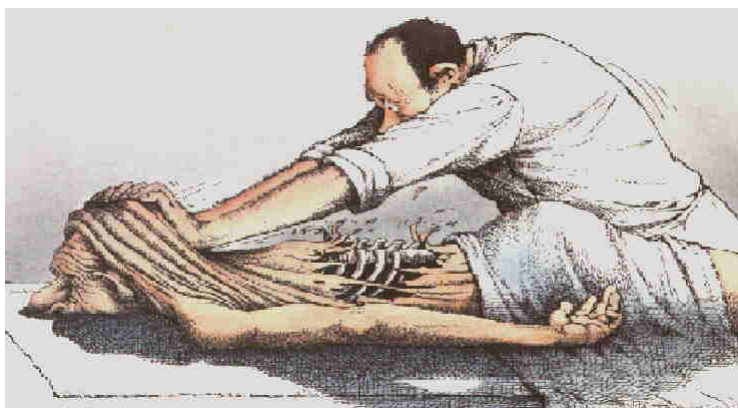
Anatomi & biomekanik



Anatomi & biomekanik



Anatomi & biomekanik



Anatomi & biomekanik

